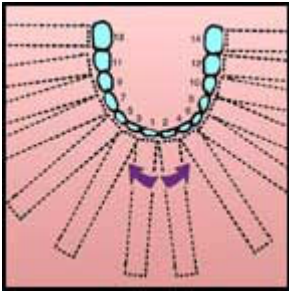


## Effective Exercises for a Short Frenum

By Sara Rosenfeld-Johnson, M.S., CCC/SLP  
Published in ADVANCE Magazine January 15, 2001



We as speech pathologists are often faced with the dilemma of feeling that a child's frenum should be clipped but meeting resistance from the medical community.

There are ways we can help medical personnel make informed decisions. Speech pathologists play a crucial role in determining the extent of frenum abnormalities, even though the decision of whether to perform corrective surgery is ultimately in the hands of medical professionals.

The frenum is the thin strand of tissue underneath the tongue that anchors the lingual musculature to the bottom of the mouth. Children with abnormally short frenums are at risk of choking when feeding and have slurred speech, because there is no or limited tongue-from-jaw dissociation.

The only medical option is surgery to clip the frenum. Although surgery is often necessary, it can sometimes be avoided. A regimen of specific stretching exercises can, in some cases, extend the reach of the frenum. They can help determine the maximum range of the frenum and provide valuable information to doctors.

The test currently used to establish frenum abnormalities frequently does not evaluate critical information. It fails to take into account the tongue-jaw dissociation necessary for normal speech and safe feeding. The testers have the individual say /t/, /d/, /l/ and /n/, tongue-tip elevation sounds, in single words, such as "hot" and "bad." If patients can say the single words clearly, they are not considered candidates for surgery.

The problem with the test is that these sounds can be made at the single-word level even if the tongue does not dissociate from the jaw. Without the dissociation, speech loses its clarity when the words are said in a sentence or in co-articulation.

To compensate, the child may develop abnormally slow speech in which the jaw moves in concert with the tongue for every tongue-tip sound. Or the child may talk at a normal rate with slurred speech, in which consonants are deleted because the tongue and jaw cannot move separately to allow the tongue tip to make contact with the alveolar ridge.

Speech therapists can employ a more effective test that takes into account the position of the jaw during function. It determines whether the tongue can move independently of the jaw and the extent of that movement.

If the tongue tip can reach the back molar when the jaw is open in the mid-jaw position, the frenum length and mobility of the tongue are considered to be within normal limits. If it cannot, there is a possibility of a frenum abnormality and the child is placed at a high risk for choking and gagging. Also, if the tongue can touch the top of the alveolar ridge on its own without the jaw moving from a low-jaw posture, the problem is not a short frenum.

If either of these movements is not possible, it's up to the speech-language pathologist to determine the limits of the frenum and work on stretching it with a series of simple exercises. The frenum has some flexibility, but the extent varies and must be determined on an individual basis.

First, using a Bite Block and each tooth as reference points, determine how far back on the bottom teeth toward the molars the tongue can reach. Have the client move his or her tongue backward in slight increments until a maximum is determined on both sides of the mouth.

To stretch the frenum, place the Bite Block slightly further back on the dental surface (no more than one tooth past where the client can normally reach) and have the client extend the tongue beyond his or her usual movement. Each treatment consists of 20 units (one to the left for every one to the right for a total of 40 movements) using the Bite-Touch exercise, which is described in my book *Oral-Motor Exercises for Speech Clarity*. When the client can

reach the target placement consistently, move back toward the next tooth.

This therapy needs to occur at least three times a week. Parents and other caregivers can supervise practice at home under the direction of a speech-language pathologist. Treatment must be continued for a minimum of four months before the extent of frenum flexibility can be ascertained.

Once the lower back molar on both sides of the mouth can be reached with the tongue tip, the therapist can begin elevation exercises. Tongue-tip elevation is necessary for the standard production of the sounds /t/, /d/, /n/ and /l/.

The exercise called "Cheerio for Tongue-Tip Elevation" is a particularly good one. Have the client work in low-jaw position. Place a Cheerio on the alveolar ridge, and instruct the client to put his or her tongue tip in the Cheerio hole. Remove your finger. The client must maintain that position with tongue-tip elevation for 50 seconds.

If progress ceases in either of these exercises, the client should be referred to a physician, along with a detailed chart of the pre-test exercises and post-test lingual capabilities. This information can help the physician make an educated decision based on

structure as well as function. The doctor likely will have the frenum clipped to allow for safe feeding and clear speech.

This surgery can dramatically improve a child's quality of life and, if needed, should be performed as early as possible so the child does not develop compensatory patterns in speech and feeding skill development.

In one case at our clinic, doctors determined that a 4-year-old was too young for clipping and that his apparently short frenum was not inhibiting his development. Using the Bite-Touch exercises, we charted his limitations. Based on this information, the child's physician recommended a frenulectomy. The surgery was performed at 9 a.m., and by noon the child was eating normally and speaking more clearly.

Even when surgery is successful, the stretching and tongue-tip elevation exercises often are still needed to establish /t/, /d/, /n/ and /l/ sounds afterward.

Whether determining frenum problems or treating oral-motor deficits resulting from short frenums, this is an opportunity for speech-language pathologists to help educate the medical community by providing concrete diagnostic treatment data.

Copyright © 2000 Sara Rosenfeld-Johnson, M.S., CCC/SLP